

crohn's colitis

Name of Clinical Care Pathway

Management of Perianal Penetrating Crohn's Disease

Objective

Provide direction to the management of patients with perianal Crohn's disease

Patient Population

Patients diagnosed with Crohn's disease with a recent surgical resection

Dr. Jeffrey McCurdy MD, PhD, FRCPC (University of Ottawa and The Ottawa Hospital)

Dr. Alain Bitton MD, FRCPC (McGill University and McGill University Health Centre)

PACE Inflammatory Bowel Disease Clinical Care Pathways

Highlight Box

- Perianal Crohn's disease is an aggressive phenotype of Crohn's disease.
- Initial investigations are aimed to assess for abscesses and differentiate between simple and complex anatomy.
- Optimal care of simple and complex fistulas requires a multidisciplinary approach involving gastroenterologists, surgeons, and radiologists.
- Anti-TNF therapy ± an immunomodulator and antibiotics remains the first line therapy for complex fistulas.
- Emerging surgical and medical therapies may be considered for refractory cases.

These clinical decision support tools were developed by Canadian experts in IBD, based on their interpretation of current evidence and considerations specific to Canadian healthcare. International guidelines from Europe and the United States are available. However, these may reflect regional factors not directly applicable in Canada.

Introduction

Perianal Crohn's disease (CD) is a form of CD which causes inflammation around the anus. Perianal manifestations of CD include perianal fistula, perianal abscess, anal canal lesions (ulcers, fissures and stricture). It affects up to a third of individuals living with CD.

Management of perianal fistulas requires a multidisciplinary approach (gastroenterology, radiology and colorectal surgery).

Symptoms include:

- Pain and/or itching around the anus
- Perianal bleeding and/or discharge (passing pus/mucus)
- Perianal pain
- Urgency to pass stools or incontinence

crohn's colitis

Fistulas can be classified as simple or complex:

- Simple perianal fistula: Low fistula defined as a tract that runs through the lower one-third of the external anal sphincter, with a single external opening without abscess or anal canal stricture.
- Complex perianal fistula: High fistula defined as a tract that runs through the upper two-thirds of the external anal sphincter, disease with multiple external openings or perianal fistulas associated with abscesses.

Therapy for perianal fistulas is guided by imaging studies and physical examinations such as pelvic magnetic resonance imaging (MRI) or rectal endoscopic ultrasound (EUS), endoscopic evaluations, and examination under anesthesia (EUA). These procedures help to define the fistula anatomy, exclude the presence of a perianal abscess and determine if there is rectal inflammation.

The goal of therapy can be divided broadly into short- and long-term goals:

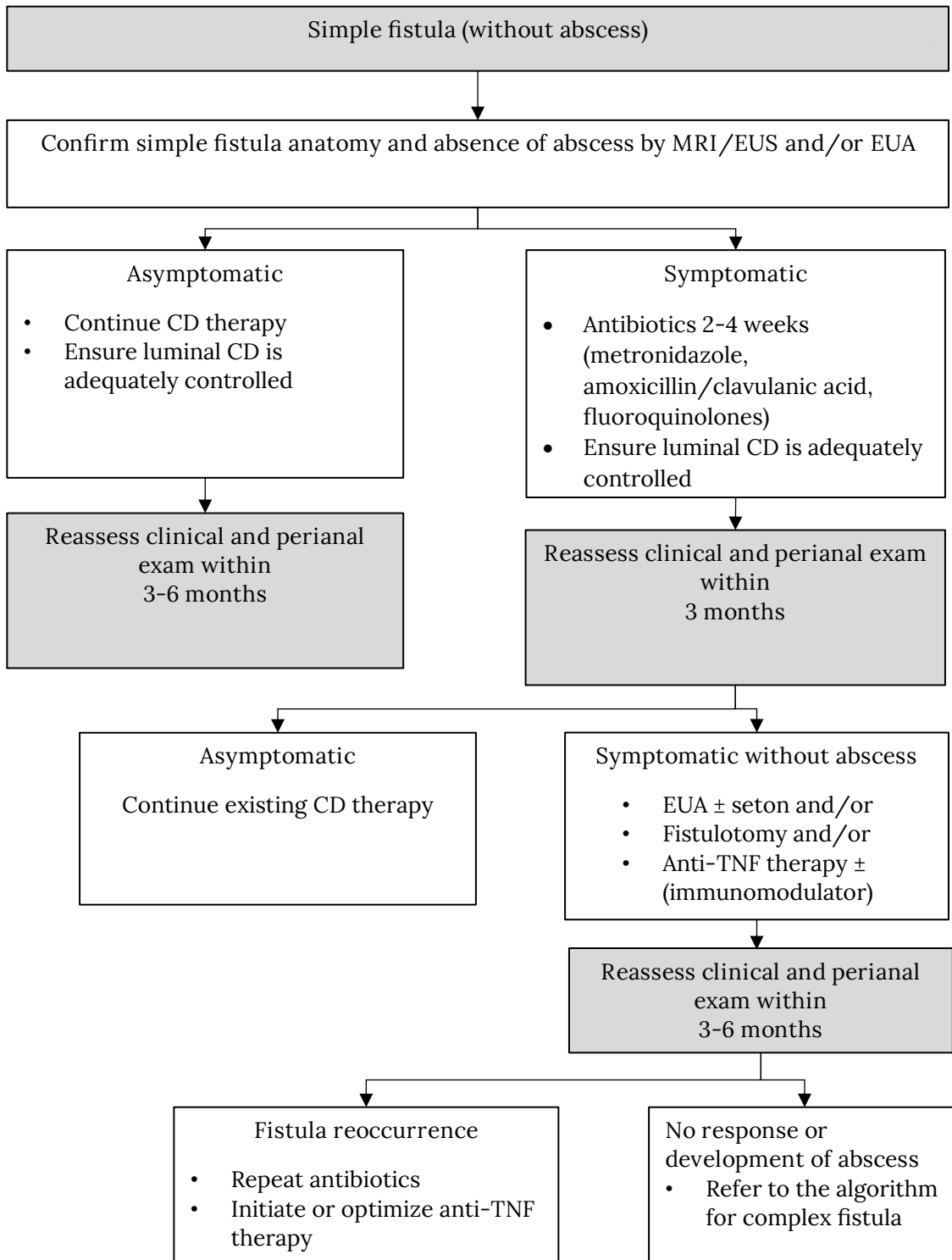
In the short term, the goal is to achieve rapid symptom relief from abscesses/fluid collections.

In the long term, treatment goals are focused on complete fistula closure without fecal incontinence.

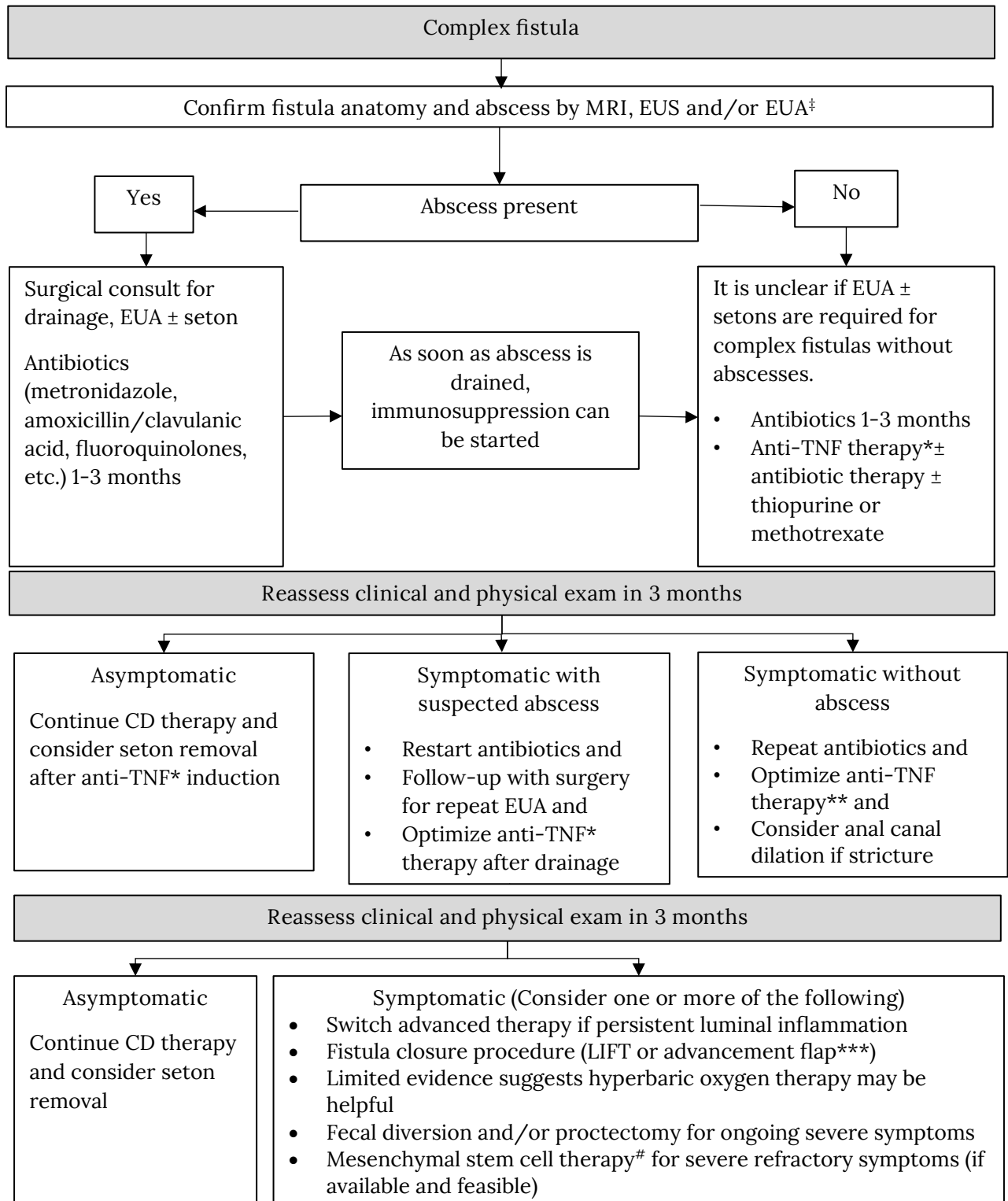
However, it is often not possible to achieve complete fistula closure. Fistula closure is determined clinically based on clinical symptoms (fistula drainage) and by physical exam by the finger compression test. To date, validated definitions of radiologic healing have yet to be established. Therefore, radiologic healing should not be considered a routine target. Symptomatic response should not be the goal of therapy but may be useful to assess early improvement with therapy. In addition, symptomatic response may be an acceptable outcome in some cases when symptoms are only intermittent and not associated with the development of the previously mentioned complications (Definition of remission and response—see Table 1).

The algorithms below are best-practice clinical pathways for the management of simple and complex perianal Fistula

crohn's colitis



crohn's colitis



‡Do not wait for an MRI/EUS/EUA if the patient has an abscess and requires definitive drainage *Optimization should be informed by TDM **Consult/discuss with your physician if you cannot tolerate anti-TNF ***Patient should not have active luminal disease and should have no active anal strictures #Conflicting evidence regarding the effectiveness of mesenchymal stem cell therapy

crohn's colitis

Table 1. Defining remission and response in patients with perianal, fistulizing CD [Adapted from Steinhart et al.]

Complete remission	Symptomatic and radiographic remission (as defined below)
Symptomatic remission	Absence of both pain and drainage from the fistula tract (absence of drainage with application of gentle pressure) and closure of the external opening
Symptomatic response	Meaningful improvement in symptoms of pain and drainage as judged by both the patient and physician in the absence of remission. Response should not be considered a desirable final outcome but is useful to assess early response to treatments.
Radiographic remission	Although a widely accepted definition of radiologic healing of perianal fistulas has yet to be established, emerging evidence suggests that fibrotic fistula tracts with an absence of inflammation and an absence of any abscess suggests radiologic healing

References

Steinhart et al. Clinical Practice Guideline for the Medical Management of Perianal Fistulizing Crohn's Disease: The Toronto Consensus IBD 2019; 25(1):1-13. <https://doi.org/10.1093/ibd/izy247>

Parks et al. A classification of fistula-in-ano. BJS Society 1976;63(1):1-12. <https://doi.org/10.1002/bjs.1800630102>

Lightner et al. Interdisciplinary Management of Perianal Crohn's Disease. Gastroenterol Clin North Am 2017; 46 (3):547-562. <https://doi.org/10.1016/j.gtc.2017.05.008>